INTEGRATED STUDY OF ISCHEMIC DILATED CARDIOPATHY: CHARACTERIZATION AND CONSOLIDATION OF ECHOCARDIOGRAPHY FOR EVALUATING CORONARY ANATOMY, AND MYOCARDIAL FUNCTION AND PERFUSION

Wilson MATHIAS Júnior

Hearth Institute

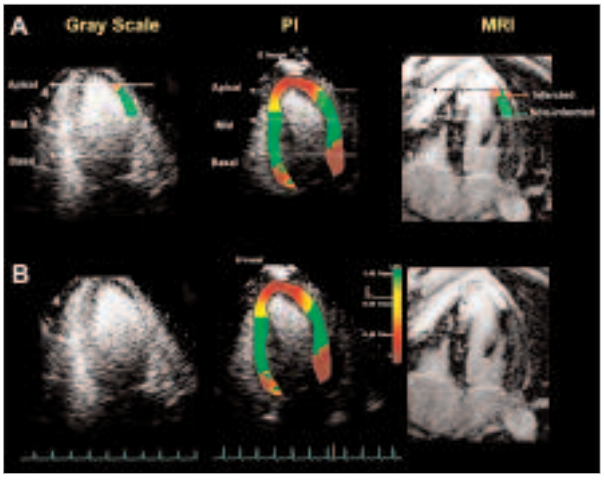

A. Myocardial contrast echocardiographic images showing how the measurement of infarct area (red) and myocardial segmental area (red + green) in the apical segment of lateral wall using Gray Scale, PI and MRI was performed. The infarct area was measured adding-up the infarct area in each infarcted myocardial segment and the total myocardial area by adding-up all 17-myocardial segmental area, in all modalities (Gray Scale, PI and MRI). B. End systolic frames from a patient with acute myocardial infarction. The infarct area in apical region is seen as a perfusion defect in Gray Scale, red color in PI, and hyperenhanced image in MRI. Gray Scale = measurement using low mechanical index gray scale; PI = parametric imaging, MRI = magnetic resonance imaging

Similarly to ischemic heart disease, dilated cardiomyophathy has a high worldwide incidence and prevalence, affecting over 1% of the world population, reaching more than 5% people over 65 years. Nowadays, the complete evaluation of the clinical data regarding coronary anatomy and functional repercussion of a given atherosclerotic lesion requires several investigative methods, frequently leading to conflicting results, high costs, and sometimes resulting in difficulties in selecting the proper treatment (clinical or surgical). In the last 30 years, the cardiovascular diagnostic methods as nuclear medicine, magnetic resonance and echocardiography turned to be fundamental tools for the diagnosis myocardial ischemia and viability. However, false results usually occurs in 20% of such studies, therefore opening the doors for new specific research in order to minimize the impact of additional costs originated from new studies or improprieties in the cardiovascular care. The present proposal for this integrated study, that includes several physiopathologic and anatomic data in patients with ischemic heart disease and dilated cardiomyophathy using modern echocardiograpic modalities (Resting 2D and 3Dimentional, and under pharmacologic stresses associated to the use of echocardiographic contrast agent) is based in a wide objective of consolodating its value among all imaging modalities. Therefore, an integrated, large scale study, designed towards the aim of demonstrating the value of each clinical and scientific information obtained through a single exam, at a reasonably low cost, is extremely desirable.

SUMMARY OF RESULTS TO DATE AND PERSPECTIVES

Three hundred and twenty six patients that underwent effective dobutamine and adenosine stress RTMPE (Real Time Myocardial Perfusion Echocardiography), were studied. Quantitative coronary angiography was performed within one month from stress test and has been analyzed in 53 patients. Accuracy of EKG, WM, qualitative MP, and quantitative MP for detecting CAD during dobutamine were 61%, 76%, 76%, and 80%, while during adenosine were 70%, 70%, 76%, and 80%, respectively.

Also, evaluating the ability of RTMPE in predicting cardiovascular events, by multivariate analysis, the only independent predictors of events were detection of WMA during dobutamine stress RTMCE (Relative Risk=4.08; p=0.043), and perfusion defect by qualitative analysis of adenosine RTMCE (Relative Risk =4,41; p = 0.036). When considering the combination of WMA and perfusion defect either by quantitative or qualitative analysis, dobutamine (Relative Risk =4,65; p = 0.031) and adenosine (Relative Risk =4,17; p = 0.041) stress RTMCE were independent predictors of events.

In another evaluation, we were challenged by the fact that quantitative myocardial perfusion echocardiography (MPE) with parametric imaging (PI), has been shown to accurately measure infarcted area in animals, but not in humans. We sought to validate MPE quantification of transmural extent and size of AMI using magnetic resonance imaging (MRI), as a gold standard. Twenty patients (12 men, 64±13 years) underwent MPE and MRI between the 2nd and 5th day post AMI. Infarct area and location, number of involved segments and transmural extent in each segment were determined by PI. Results were compared to late enhanced MRI. There was 99% agreement between both methods regarding the segmental location. The correlation between infarct area by MRI and PI was 0.87;p< 0.001. The correlation between transmural extent by MRI and PI was 0.89;p<0.001.

MAIN PUBLICATIONS

Rodrigues AC, Hotta VT, Borges Neto FM, dos Santos JM, Trindade ML, Mathias W Jr. 2008. A randomized double-blind placebo-controlled trial to increase feasibility of dobutamine stress echocardiography in patients with hypertension. *J Am Soc Echocardiogr*. **21(4)**:327-30.

Tsutsui JM, Falcão SN, Dourado PM, Lima MF, Alves AA, Guerra VC, Ramires JA, Mathias W. 2007. Gender differences in chronotropic and hemodynamic responses during dobutamine-atropine stress echocardiography. *Echocardiography*. **24(8)**:843-50.

Tsutsui JM, Mathias W Jr. 2007. Clinical use of contrast echocardiography with microbubble-based. *Arq Bras Cardiol*. **88(5)**:e132-8.

Kowatsch I, Tsutsui JM, Osório AF, Uchida AH, Machiori GG, Lopes ML, César LA, Ramires JA, Mathias W Jr. 2007. Head-to-head comparison of dobutamine and adenosine stress real-time myocardial perfusion echocardiography for the detection of coronary artery disease. *J Am Soc Echocardiogr*. **20(9)**:1109-17.

Osório AF, Tsutsui JM, Kowatsch I, Guerra VC, Ramires JA, Lemos PA, Cesar LA, Mathias W Jr. 2007. Evaluation of blood flow reserve in left anterior descending coronary artery territory by quantitative myocardial contrast and Doppler echocardiography. *J Am Soc Echocardiogr*. **20(6)**:709-16.

Cesar LA, Mathias W Jr, Armaganijan D, Gimenez V, Jallad S, Del Monaco MI, Bicudo L, Meneguin S, Gomes EP, Brasil CK, Ramires JF. 2007. Trimetazidine to reverse ischemia in patients with class I or II angina: a randomized, double-blind, placebo-controlled dobutamine-atropine stress echocardiography study. *Coron Artery Dis*. **8(4)**:259-63.

Vieira ML, Maddukuri P, Pandian NG, Mathias W Jr, Ramires JA.2006. Saddle shape of mitral valve annulus: three-dimensional transthoracic echocardiography. *Arq Bras Cardiol*. **87(5)**:e215-6.

Vieira ML, Pomerantzeff PM, Brandão CM, Grinberg M, Mathias W Jr, Ramires JA. 2007. Three-dimensional transesophageal echocardiographic imaging of mitral valve bioprosthesis leaflets perforation due to infective endocarditis. *Arq Bras Cardiol*. **88(1)**:e21.

Wilson MATHIAS Júnior

Instituto do Coração
Avenida Dr. Enéas de Carvalho Aguiar, nº 44
Cerqueira Cesar
CEP 05403-000 – São Paulo, SP – Brasil

+55-11-3069-5646
wmathias@incor.usp.br